

Founded by Richard C. Cabot

Eric S. Rosenberg, M.D., *Editor*
Jo-Anne O. Shepard, M.D., *Associate Editor*
Sally H. Ebeling, *Assistant Editor*

Nancy Lee Harris, M.D., *Editor*
Alice M. Cort, M.D., *Associate Editor*
Emily K. McDonald, *Assistant Editor*



Case 4-2015: A 49-Year-Old Man with Obtundation Followed by Agitation and Acidosis

Cynthia M. Cooper, M.D., and Jason M. Baron, M.D.

PRESENTATION OF CASE

Dr. Meredith Eicken (Medicine–Pediatrics): A 49-year-old man was admitted to this hospital after being found outdoors in early autumn with obtundation, followed by increasing agitation.

On the afternoon of admission, the patient was found leaning up against a wall, unresponsive. With him was a half-filled bottle of cloudy liquid with possible pill fragments, as well as bottles of prescription medications that had been filled earlier that day, including trazodone (1 of 28 pills remaining) and risperidone, buspirone, and loratadine (each with all pills present). Emergency medical services were called. On examination of the patient in the field, the Glasgow Coma Scale (GCS) score was 4 on a scale of 3 to 15 (with lower scores indicating a lower level of consciousness); he opened his eyes in response to painful stimuli but did not move or make any sounds. The blood pressure was 108/67 mm Hg, the pulse 90 beats per minute and regular, the respiratory rate 10 breaths per minute, and the oxygen saturation 97%. The skin was pink, warm, and dry, and the pupils were 3 mm in diameter, round, and reactive to light; the remainder of the examination was reportedly normal. The capillary blood glucose level was 108 mg per deciliter. Oxygen (at a rate of 15 liters per minute, delivered by means of a nonrebreather face mask) and naloxone were administered, without improvement in mental status. An electrocardiogram (ECG) was normal. He was transported to this hospital by ambulance.

The patient's history, which was obtained from his medical records, included drug use (cocaine, opiates, and benzodiazepines), anxiety, depression with multiple suicide attempts, hepatitis C virus infection, and possible chronic obstructive pulmonary disease (COPD). Current medications other than those found with him on presentation were unknown. He had no known allergies. He smoked cigarettes and had been homeless and incarcerated in the past. He was divorced and had adult children; his current living circumstances were not known.

On examination in the emergency department, the patient could move his arms and legs and open his eyes in response to painful stimuli, but he could not follow commands or speak; the GCS score was 8. The blood pressure was 108/67 mm Hg,

From the Departments of Medicine (C.M.C.) and Pathology (J.M.B.), Massachusetts General Hospital, and the Departments of Medicine (C.M.C.) and Pathology (J.M.B.), Harvard Medical School — both in Boston.

N Engl J Med 2015;372:465-73.

DOI: 10.1056/NEJMcp1410940

Copyright © 2015 Massachusetts Medical Society.

Table 1. Laboratory Data.*

Variable	Reference Range, Adults†	On Presentation, Emergency Department	7.5 Hr after Presentation	10 Hr after Presentation
Sodium (mmol/liter)	135–145	141	142	146
Potassium (mmol/liter)	3.4–4.8	4.2	4.2	4.3
Chloride (mmol/liter)	100–108	96	100	105
Carbon dioxide (mmol/liter)	23.0–31.9	23.9	8.3	5.7
Plasma anion gap (mmol/liter)	3–15	21	34	35
Glucose (mg/dl)	70–110	98	107	99
Urea nitrogen (mg/dl)	8–25	9	8	8
Creatinine (mg/dl)	0.6–1.50	1.12	1.24	1.26
Magnesium (mg/dl)	1.7–2.4	2.1	3.2	2.7
Plasma lactic acid (mmol/liter)	0.5–2.2			9.0
Osmolality (mOsm/kg of water)	280–296			394
Venous blood gases				
Inspired oxygen			Ambient air	
Base excess (mmol/liter)			-16.1	
pH	7.30–7.40		7.23	
Partial pressure of oxygen (mm Hg)	35–50		53	
Partial pressure of carbon dioxide (mm Hg)	38–50		22	

* To convert the values for glucose to millimoles per liter, multiply by 0.05551. To convert the values for urea nitrogen to millimoles per liter, multiply by 0.357. To convert the values for creatinine to micromoles per liter, multiply by 88.4. To convert the values for magnesium to millimoles per liter, multiply by 0.4114.

† Reference values are affected by many variables, including the patient population and the laboratory methods used. The ranges used at Massachusetts General Hospital are for adults who are not pregnant and do not have medical conditions that could affect the results. They may therefore not be appropriate for all patients.

the pulse 88 beats per minute, the temperature 36.2°C, the respiratory rate 15 breaths per minute, and the oxygen saturation 97% while he was breathing ambient air. Both pupils measured 3 mm in diameter and were briskly reactive to 2 mm when exposed to bright light. The lungs were clear with normal respiratory effort, the breath sounds were diminished at the bases, the heart sounds were normal, and the abdomen was soft. Within the first 45 minutes after his arrival at the hospital, the patient became increasingly agitated and combative, resisting all medical interventions; physical restraints were applied. An ECG showed sinus rhythm at a rate of 86 beats per minute, with evidence of biatrial enlargement and with a PR interval of 128 msec, a QRS interval of 104 msec, a QT interval of 386 msec, and a corrected QT (QTc) interval of 461 msec. A complete blood count and blood levels of calcium and phosphorus were normal; other test results are shown in

Table 1. Analysis of urine obtained by means of straight catheterization revealed a pH of 5.5 and a specific gravity of 1.008; dipstick testing was normal. Screening of a blood specimen for toxins revealed trazodone (1826 µg per liter; therapeutic range, 800 to 1600), meta-chlorophenylpiperazine (MCP), and venlafaxine; screening of a urine specimen was negative. The poison control center advised monitoring cardiac intervals with serial ECG. Approximately 4 hours after arrival, a repeat ECG showed a QTc interval of 501 msec. Shortly thereafter, the patient vomited. Magnesium was administered.

On admission, the patient had intermittent somnolence alternating with periods of increasing agitation and thrashing limbs, but he remained nonverbal and unable to follow commands. Low-dose lorazepam for extreme agitation and normal saline were administered. Increasing lower abdominal fullness developed that was consistent

with bladder distention and urinary retention; an indwelling urinary catheter was placed, with improvement. On repeat blood testing 7.5 hours after presentation, blood levels of calcium, phosphorus, total protein, albumin, globulin, and troponin T were normal, as were results of liver-function tests; other test results are shown in Table 1. The blood pressure was 109/64 mm Hg, and the pulse 105 beats per minute; the temperature, respiratory rate, and oxygen saturation were normal. Ten hours after presentation, blood levels of calcium, phosphorus, and creatine kinase were normal; additional laboratory test results are shown in Table 1.

A diagnostic test was performed.

DIFFERENTIAL DIAGNOSIS

Dr. Cynthia M. Cooper: This 49-year-old man presented with obtundation, followed by periods of agitation. Since he was unable to describe the events leading up to his presentation, review of his medical records was necessary in order to establish a context for the current clinical encounter. Bedside observation further informs this clinical context, adding critical information about the time of onset and progression of the current illness. Easy access to laboratory and imaging evaluation has made careful observation a fading art.¹ However, there is usually important information in the initial description of the patient's appearance that may provide clues to help determine the duration of illness by indicating, for example, when the patient last felt well. In particular, beard growth and the condition of the nails can indicate when the patient was well enough to attend to usual grooming habits. These are some of the many clues that can reveal the time course of the illness beyond the information provided in the history.

FIRST CONTACT

The patient is a middle-aged man who was found propped up against a wall outdoors in autumn. His vital signs were normal but he had obtundation, with a GCS score of 4. Prescription bottles and a half-filled bottle of an unknown cloudy fluid were next to him.

A wealth of information is contained just in this description. The fact that he was able to fill medication prescriptions earlier that day serves as an anchor point; his cognitive function had last

been intact within hours before this first examination. The pill bottles not only provide the patient's name and the contact information for his pharmacy and providers but also suggest a history of depression, anxiety, insomnia, and atopy.

The initial examination narrows the differential diagnosis. The patient was outdoors at first encounter but was neither hypothermic nor hyperthermic. The initial survey revealed no apparent trauma, and his posture and the absence of incontinence reduce the likelihood of a postictal state. Infection and metabolic derangement remain possible diagnoses despite the normal vital signs and glucose level obtained on point-of-care testing.

Pink, dry skin and normal oxygen saturation are features of carbon monoxide poisoning, but this is an unlikely diagnosis because the patient was found outdoors. Pink, dry skin can also be a manifestation of anticholinergic overdose but typically occurs along with mydriasis and an abnormal ECG. Miosis is suggestive of narcotic overdose but would be expected to be reversed after the administration of naloxone.

Trazodone overdose was suspected at first contact but is unlikely to explain such substantial obtundation. Trazodone overdose in the absence of ingestion of other substances rarely is life-threatening or results in permanent injury.² Deaths related to isolated trazodone ingestion are primarily caused by cardiac arrhythmias due to prolongation of the QTc interval or by development of the serotonin syndrome with multiorgan failure. Surviving patients typically have either no symptoms or minimal symptoms of lethargy and intoxication.³⁻⁶

ON PRESENTATION TO THE EMERGENCY DEPARTMENT

Assessment in the emergency department began within an hour after the first contact. The examination was notable for normal vital signs and an improved GCS score. After 45 minutes, the patient became combative and agitated, requiring mechanical restraint and sedation. This rapid progression from obtundation to agitation further narrows the differential diagnosis. Encephalitis, particularly that due to herpes simplex virus, can cause behavioral changes and agitation, although these symptoms are typically accompanied by fever. Abrupt reversal of narcotic overdose can result in rapid change from obtundation to agi-

tation; however, naloxone had previously produced no effect. The short time course would not be consistent with delirium tremens due to alcohol withdrawal. A paradoxical response to benzodiazepines is idiosyncratic and unpredictable, but in this case, agitation preceded receipt of lorazepam.⁷⁻⁹

Initial blood tests were notable for an elevated anion gap and normal levels of bicarbonate and albumin. This combination of results could be explained by either an excess of unmeasured anions or a paucity of unmeasured cations, although the latter scenario is less likely, given that the serum levels of calcium, potassium, and magnesium were all normal. A third possibility is a high anion-gap metabolic acidosis superimposed on a metabolic alkalosis.¹⁰ Loss of gastric secretions through vomiting could explain metabolic alkalosis in this patient, although the expected hypokalemia and azotemia are absent. The possible history of COPD suggests chronic retention of carbon dioxide, which can lead to a compensatory metabolic alkalosis.

In addition to trazodone, MCPP and venlafaxine were detected on the toxicologic screening. MCPP is an active metabolite of trazodone with complex neurochemical effects similar to those caused by the hallucinogen 3,4-methylenedioxy-methamphetamine (MDMA, or “ecstasy”).¹¹ MCPP can cause dysphoria, anxiety, and panic, as well as shivering, increased heart rate, and increased pupillary size.¹²⁻¹⁴ Venlafaxine overdose can cause depression of the central nervous system and induce the serotonin syndrome.¹⁵ Hypoglycemia and rhabdomyolysis are metabolic consequences of venlafaxine overdose^{16,17}; tachycardia and hypertension are common, and QTc prolongation has been reported, particularly among men and patients with heart failure.^{18,19} Ingestion of MCPP, venlafaxine, or both could explain the patient’s agitation but not the anion-gap metabolic acidosis.

4 HOURS AFTER PRESENTATION

Four hours after presentation, clinically significant QTc prolongation, a feature of both trazodone and venlafaxine overdose, had developed.^{4,5,18} Emesis is a nonspecific symptom with many causes, although in a patient with suspected anion-gap metabolic acidosis, it could suggest progressive metabolic disarray.²⁰ Urinary retention is not a feature of intoxication with trazodone, MCPP, or venlafaxine; its development might suggest un-

derlying prostate enlargement, which is not uncommon among men of this patient’s age.^{21,22}

7.5 HOURS AFTER PRESENTATION

Measurements of venous blood gases were obtained 7.5 hours after presentation. Measurements of venous blood gases have been shown to be reliable substitutes for measurements of arterial blood gases with respect to the pH, partial pressure of carbon dioxide (Pco₂), and bicarbonate level. Venous pH is typically 0.02 to 0.04 lower than arterial pH, and venous Pco₂ is approximately 5 to 8 mm Hg higher than arterial Pco₂.²³ This patient had acidemia (pH 7.23) and a low Pco₂ (22 mm Hg), findings that are consistent with metabolic acidosis and appropriate respiratory compensation.^{24,25}

Respiratory compensation is caused by augmentation of alveolar ventilation due to an increase in tidal volume, respiratory rate, or both. Are the descriptions of “normal respirations” and “normal respiratory effort” in the case history correct, given these physiological features? The respiratory rate is an important vital sign that is predictive of both respiratory and nonrespiratory outcomes.²⁶⁻²⁸ Tachypnea is a key predictor of clinical deterioration during hospitalization and of poor outcomes after discharge.²⁹⁻³² Yet the recorded respiratory rate is often unreliable.^{33,34}

Other laboratory test results obtained 7.5 hours after presentation showed an increase in the serum anion gap, from 21 to 34 mmol per liter, and a drop in the serum bicarbonate level, from 23.9 to 8.3 mmol per liter. The change in the serum bicarbonate level is greater than the change in the anion gap, suggesting a concurrent non-anion gap metabolic acidosis. Previous testing has limited the differential diagnosis for the anion-gap acidosis (Table 2). The patient had normal renal function and no urinary ketones; he had no history of bowel disease or surgery that would predispose him to D-lactic acidosis. The screening for toxins was negative for salicylates and acetaminophen.³⁵

10 HOURS AFTER PRESENTATION

The laboratory test results obtained 10 hours after presentation reflected a small increase in the serum anion gap, from 34 to 35 mmol per liter, and a further drop in the serum bicarbonate level, from 8.3 to 5.7 mmol per liter. A drop in the serum bicarbonate level that is greater than the

Table 2. Differential Diagnosis for High Anion-Gap Metabolic Acidosis in This Patient.

L-Lactic acidosis
D-Lactic acidosis
Ketoacidosis
Chronic kidney disease
Salicylate ingestion
Pyroglutamic acidosis
Toxic alcohol ingestion

rise in the anion gap suggests an additional non-anion gap metabolic acidosis that is most likely due to the saline infusion.

At this time, the plasma lactic acid level was 9.0 mmol per liter. Could this explain the high anion-gap metabolic acidosis? A key feature of lactic acidosis is the time-dependent difference between the change in the anion gap and the change in the serum bicarbonate level. Initially, lactate raises the anion gap and lowers the serum bicarbonate level in a 1:1 ratio. Over time, hydrogen ions are buffered intracellularly, and the acidosis promotes generation of renal bicarbonate, shifting the ratio of the change in the anion gap to the change in the bicarbonate level closer to 1.8:1.¹⁰ Thus, the lactate level of 9 mmol per liter alone does not account for the rise in the anion gap and the fall in the bicarbonate level seen 10 hours after presentation.

SUMMARY

Classification of a high anion-gap metabolic acidosis by the presence or absence of a serum osmolal gap can further narrow the differential diagnosis.³⁶ According to the laboratory test results that were obtained 10 hours after presentation, including normal levels of blood urea nitrogen and serum glucose, the calculated serum osmolality is 300 mOsm per kilogram of water. The difference between the measured and the calculated serum osmolality is 94 mOsm per kilogram of water, which is much higher than the osmolal gap typically seen in patients with lactic acidosis.³⁷ This high osmolal gap suggests that the patient had ingested an alcohol that was not measured on the initial toxicologic screening, such as propylene glycol or ethylene glycol.

Propylene glycol is the carrier of intravenous lorazepam and has been implicated in anion-gap metabolic acidosis in patients in the intensive

care unit. However, anion-gap metabolic acidosis typically occurs when high doses of intravenous lorazepam are administered for 24 hours or longer. Because of the 10-hour time frame in this case, toxicity due to propylene glycol from intravenous lorazepam is unlikely.³⁸

Ethylene glycol has an intoxicating effect similar to that of ethanol and is metabolized by alcohol dehydrogenase. The parent alcohol produces an osmolal gap. This osmolal gap declines over time, and an anion-gap metabolic acidosis develops as ethylene glycol is metabolized to glycolate and oxalate. Ethylene glycol is not routinely checked in serum toxicologic screenings and is a possible cause that should be considered even before laboratory test results are available.^{39,40} The metabolite of ethylene glycol is similar in structure to lactate and therefore can be misinterpreted on laboratory tests.^{41,42} Since the high osmolal gap is unlikely to be explained by propylene glycol intoxication, I think ethylene glycol intoxication is the most likely diagnosis in this patient.

Why did this patient present with self-injurious behavior at this point in his life? He had multiple risk factors for suicide, including mental illness, homelessness, substance abuse, and prior incarceration.⁴³⁻⁴⁶ The rate of completed suicide appears to vary seasonally, with a peak in spring and a lesser peak in autumn.^{47,48} Although we will probably never know why this patient presumably wanted to end his life, it seems likely that the ingestion of ethylene glycol was attempted suicide.

Dr. Eric S. Rosenberg (Pathology): Dr. Eicken, what was your impression when you evaluated this patient?

Dr. Eicken: Given the limited available history, we considered several possible causes for his altered mental status, including structural neurologic abnormalities, infection, and toxic or metabolic derangements. There were no external signs of trauma and the neurologic examination revealed no focal motor deficits, but a structural intracranial abnormality could not be entirely ruled out because head imaging had not been performed. Meningoencephalitis was considered; however, the rapid decline of his condition, his overall clinical appearance, and the absence of fever and leukocytosis were not consistent with this diagnosis. Initially, there were no overt metabolic derangements. Therefore, we suspected a

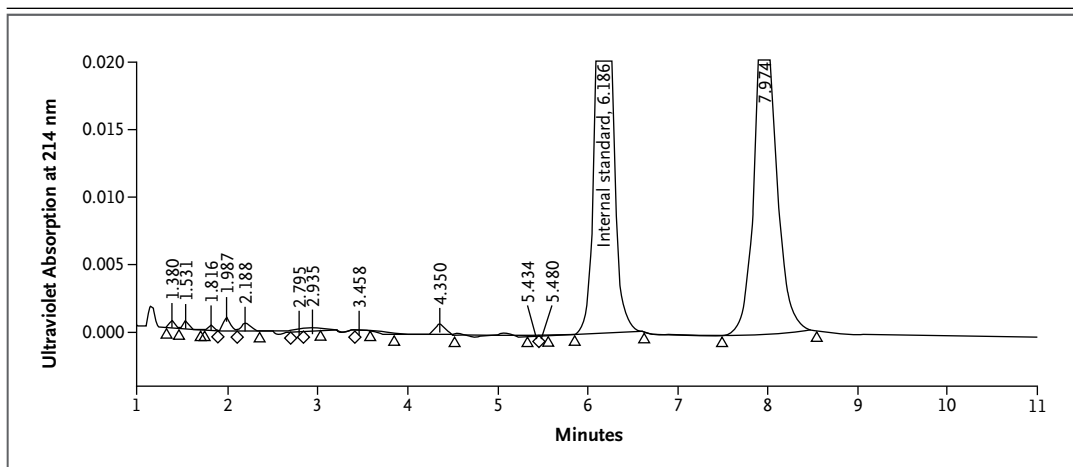


Figure 1. Serum Toxicologic Screening.

Serum toxicologic screening was performed with the use of high-performance liquid chromatography. The patient's absorbance peak at 7.974 minutes matches the trazodone standard in retention time and ultraviolet spectrum (spectrum not shown). The trazodone level was quantified by calculating the ratio of the peak amplitude for trazodone to the internal standard peak amplitude (6.186 minutes) and comparing it with the trazodone–internal standard amplitude ratio from a calibrator containing a known trazodone level.

toxicologic cause. A depressed mental status can be seen with both the serotonin syndrome and the neuroleptic malignant syndrome, and he had medications in his possession that could cause each of these syndromes. However, the absence of hyperpyrexia, characteristic neurologic findings such as rigidity and clonus, and autonomic instability suggests that these diagnoses are unlikely. Polypharmacy could lead to a mixed toxic syndrome, but the toxicologic screening did not support this diagnosis.

We thought that toxic alcohol ingestion was the likely diagnosis. Laboratory test results obtained over time showed the development of a worsening anion-gap metabolic acidosis, as well as elevated lactate levels, markedly elevated serum osmolality with an osmolal gap, and negative results of toxicologic screening for other alcohols; these findings made ethylene glycol ingestion our top diagnostic consideration.

CLINICAL DIAGNOSIS

Ethylene glycol ingestion.

DR. CYNTHIA M. COOPER'S DIAGNOSES

Trazodone overdose.

High anion-gap metabolic acidosis and high

serum osmolal gap due to ethylene glycol ingestion.

PATHOLOGICAL DISCUSSION

Dr. Jason M. Baron: Serum toxicologic screening, performed by means of high-performance liquid chromatography,⁴⁹ was positive for trazodone (Fig. 1) and its metabolite MCPP. The trazodone level was suprathereapeutic at 1826 μg per liter. Urine toxicologic screening, performed by means of immunoassay, was negative for common drugs of abuse, including amphetamines. MCPP cross-reacts with the antibodies used in the detection of amphetamines in some immunoassays.^{50,51} Although the urinary amphetamine assay used at this hospital is relatively sensitive for the detection of MCPP and false positive results can be obtained even when trazodone levels are within the therapeutic range,⁵¹ the negative amphetamine assay in this case may be explained by a relatively diluted urine specimen.

Serum toxicologic screening was negative for ethanol, methanol, and isopropanol. Ethylene glycol (boiling point, 197°C) is much less volatile than methanol, ethanol, and isopropanol (boiling points, 65°C, 78°C, and 83°C, respectively) and cannot be detected on this hospital's volatile-alcohol assay, which is performed with the use of gas chromatography with a maximum

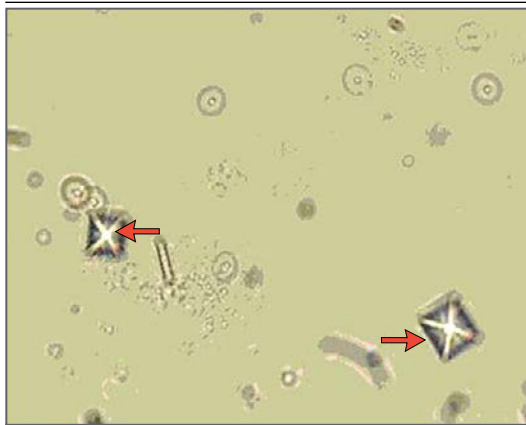


Figure 2. Urine Sediment.

A photomicrograph of the patient's urine sediment shows envelope-shaped crystals (arrows). The morphologic features are consistent with those of calcium oxalate crystals (dihydrate form) caused by ethylene glycol ingestion.

column-oven temperature of 115°C. A serum specimen collected approximately 10 hours after presentation was sent to an outside reference laboratory with a gas chromatography assay capable of detecting ethylene glycol. This specimen revealed an ethylene glycol level of 351 mg per deciliter (toxic value, ≥ 20 mg per deciliter).

Examination of the sediment of a urine sample collected approximately 12 hours after presentation revealed calcium oxalate crystals (Fig. 2). Ethylene glycol is metabolized to oxalic acid, which binds to calcium, leading to calcium oxalate crystalluria.⁵² Urinary calcium oxalate crystals are commonly associated with ethylene glycol toxicity,⁵² but this finding is nonspecific.

FOLLOW-UP

Dr. Rosenberg: Dr. Eicken, would you tell us what happened with the patient?

Dr. Eicken: Given our clinical suspicion that ethylene glycol ingestion was the likely diagnosis, we rapidly initiated treatment with intravenous bicarbonate and fomepizole. The patient was transferred to the intensive care unit, where he

was intubated for airway protection and underwent emergency hemodialysis. He was extubated without complication after 2 days and did not have prolonged renal failure. Fomepizole was continued for 4 days, until the ethylene glycol was undetectable; the patient was then transferred to the psychiatry service for continued care.

During the remainder of his hospital stay, the patient received electroconvulsive therapy, and both he and his providers noted clinical improvement. Unfortunately, he did not return for scheduled sessions of electroconvulsive therapy after discharge and was lost to follow-up until the winter, when he presented again to the emergency department with suicidal ideation. He was living in a "sober house" (a facility for people recovering from substance abuse) but had started using cocaine and heroin. Since that visit, his records show additional visits to the emergency department for suicidal ideation and intermittent psychiatric hospitalizations.

A Physician: Did you consider performing a lumbar puncture early in the evaluation, since it was impossible to rule out meningitis on a clinical basis?

Dr. Eicken: Lumbar puncture was considered, but the degree of the patient's agitation at the time prevented us from safely performing the procedure. Ideally, we would have had the results of a computed tomographic scan of the head before the procedure. Had we not obtained data suggesting a diagnosis of toxic alcohol ingestion as rapidly as we did, I think an argument could have been made for starting empirical antimicrobial therapy.

FINAL DIAGNOSIS

Ethylene glycol ingestion.

This case was presented at the Medical Case Conference.

No potential conflict of interest relevant to this article was reported.

Disclosure forms provided by the authors are available with the full text of this article at NEJM.org.

We thank Dr. Muthiah Vaduganathan for the photograph of the calcium oxalate crystals, and Dr. James Flood for review of the toxicologic data.

REFERENCES

- Naghshineh S, Hafler JP, Miller AR, et al. Formal art observation training improves medical students' visual diagnostic skills. *J Gen Intern Med* 2008;23:991-7.
- Mowry JB, Spyker DA, Cantilena LR Jr, Bailey JE, Ford M. 2012 Annual Report of the American Association of Poison Control Centers' National Poison Data System (NPDS): 30th annual report. *Clin Toxicol (Phila)* 2013;51:949-1229.
- Martínez MA, Ballesteros S, Sánchez de la Torre C, Almarza E. Investigation of

- a fatality due to trazodone poisoning: case report and literature review. *J Anal Toxicol* 2005;29:262-8.
4. Service JA, Waring WS. QT prolongation and delayed atrioventricular conduction caused by acute ingestion of trazodone. *Clin Toxicol (Phila)* 2008;46:71-3.
 5. Dattilo PB, Nordin C. Prolonged QT associated with an overdose of trazodone. *J Clin Psychiatry* 2007;68:1309-10.
 6. Chung KJ, Wang YC, Liu BM, Supernaw RB. Management of ventricular dysrhythmia secondary to trazodone overdose. *J Emerg Med* 2008;35:171-4.
 7. Hall RC, Zisook S. Paradoxical reactions to benzodiazepines. *Br J Clin Pharmacol* 1981;11:Suppl 1:99S-104S.
 8. Weinbroum AA, Szold O, Ogorek D, Flaishon R. The midazolam-induced paradox phenomenon is reversible by flumazenil: epidemiology, patient characteristics and review of the literature. *Eur J Anaesthesiol* 2001;18:789-97.
 9. Robin C, Trieger N. Paradoxical reactions to benzodiazepines in intravenous sedation: a report of 2 cases and review of the literature. *Anesth Prog* 2002;49:128-32.
 10. Kraut JA, Madias NE. Serum anion gap: its uses and limitations in clinical medicine. *Clin J Am Soc Nephrol* 2007;2:162-74.
 11. Hamik A, Peroutka SJ. 1-(m-chlorophenyl)piperazine (mCPP) interactions with neurotransmitter receptors in the human brain. *Biol Psychiatry* 1989;25:569-75.
 12. Gijssman HJ, Van Gerven JM, Tieleman MC, et al. Pharmacokinetic and pharmacodynamic profile of oral and intravenous meta-chlorophenylpiperazine in healthy volunteers. *J Clin Psychopharmacol* 1998;18:289-95.
 13. Feuchtl A, Bagli M, Stephan R, et al. Pharmacokinetics of m-chlorophenylpiperazine after intravenous and oral administration in healthy male volunteers: implication for the pharmacodynamic profile. *Pharmacopsychiatry* 2004;37:180-8.
 14. Kovaleva J, Devuyst E, De Paepe P, Verstraete A. Acute chlorophenylpiperazine overdose: a case report and review of the literature. *Ther Drug Monit* 2008;30:394-8.
 15. Bosse GM, Spiller HA, Collins AM. A fatal case of venlafaxine overdose. *J Med Toxicol* 2008;4:18-20.
 16. Francino MC, Bretaudeau Deguigne M, Badin J, Turcant A, Perrotin D. Hypoglycaemia: a little known effect of venlafaxine overdose. *Clin Toxicol (Phila)* 2012;50:215-7.
 17. Wilson AD, Howell C, Waring WS. Venlafaxine ingestion is associated with rhabdomyolysis in adults: a case series. *J Toxicol Sci* 2007;32:97-101.
 18. Howell C, Wilson AD, Waring WS. Cardiovascular toxicity due to venlafaxine poisoning in adults: a review of 235 consecutive cases. *Br J Clin Pharmacol* 2007;64:192-7.
 19. Batista M, Dugernier T, Simon M, et al. The spectrum of acute heart failure after venlafaxine overdose. *Clin Toxicol (Phila)* 2013;51:92-5.
 20. Kalantar-Zadeh K, Uppot RN, Lewandowski KB. Case Records of the Massachusetts General Hospital (Case 23-2013). *N Engl J Med* 2013;369:374-82.
 21. Arrighi HM, Metter EJ, Guess HA, Fozzard JL. Natural history of benign prostatic hyperplasia and risk of prostatectomy. *Urology* 1991;38:Suppl:4-8.
 22. Chute CG, Panser LA, Girman CJ, et al. The prevalence of prostatism: a population-based survey of urinary symptoms. *J Urol* 1993;150:85-9.
 23. Morris CG, Low J. Metabolic acidosis in the critically ill: part 1. Classification and pathophysiology. *Anaesthesia* 2008;63:294-301.
 24. Albert MS, Dell RB, Winters RW. Quantitative displacement of acid-base equilibrium in metabolic acidosis. *Ann Intern Med* 1967;66:312-22.
 25. Fulop M. A guide for predicting arterial CO₂ tension in metabolic acidosis. *Am J Nephrol* 1997;17:421-4.
 26. Dellinger RP, Levy MM, Rhodes A, et al. Surviving Sepsis Campaign: international guidelines for management of severe sepsis and septic shock: 2012. *Crit Care Med* 2013;41:580-637.
 27. Fine MJ, Auble TE, Yealy DM, et al. A prediction rule to identify low-risk patients with community-acquired pneumonia. *N Engl J Med* 1997;336:243-50.
 28. Lim WS, van der Eerden MM, Laing R, et al. Defining community acquired pneumonia severity on presentation to hospital: an international derivation and validation study. *Thorax* 2003;58:377-82.
 29. Churpek MM, Yuen TC, Edelson DP. Risk stratification of hospitalized patients on the wards. *Chest* 2013;143:1758-65.
 30. Churpek MM, Yuen TC, Park SY, Meltzer DO, Hall JB, Edelson DP. Derivation of a cardiac arrest prediction model using ward vital signs. *Crit Care Med* 2012;40:2102-8.
 31. Dommasch M, Sinnecker D, Barthel P, et al. Nocturnal respiratory rate predicts non-sudden cardiac death in survivors of acute myocardial infarction. *J Am Coll Cardiol* 2014;63:2432-3.
 32. Barthel P, Wensel R, Bauer A, et al. Respiratory rate predicts outcome after acute myocardial infarction: a prospective cohort study. *Eur Heart J* 2013;34:1644-50.
 33. Bianchi W, Dugas AF, Hsieh YH, et al. Revitalizing a vital sign: improving detection of tachypnea at primary triage. *Ann Emerg Med* 2013;61:37-43.
 34. Semler MW, Stover DG, Copland AP, et al. Flash mob research: a single-day, multicenter, resident-directed study of respiratory rate. *Chest* 2013;143:1740-4.
 35. Humphreys BD, Forman JP, Zandi-Nejad K, Bazari H, Seifter J, Magee CC. Acetaminophen-induced anion gap metabolic acidosis and 5-oxoprolinuria (pyroglutamic aciduria) acquired in hospital. *Am J Kidney Dis* 2005;46:143-6.
 36. Kraut JA, Xing SX. Approach to the evaluation of a patient with an increased serum osmolal gap and high-anion-gap metabolic acidosis. *Am J Kidney Dis* 2011;58:480-4.
 37. Schelling JR, Howard RL, Winter SD, Linas SL. Increased osmolal gap in alcoholic ketoacidosis and lactic acidosis. *Ann Intern Med* 1990;113:580-2.
 38. Horinek EL, Kiser TH, Fish DN, MacLaren R. Propylene glycol accumulation in critically ill patients receiving continuous intravenous lorazepam infusions. *Ann Pharmacother* 2009;43:1964-71.
 39. Oostvogels R, Kemperman H, Hubeek I, ter Braak EW. The importance of the osmolality gap in ethylene glycol intoxication. *BMJ* 2013;347:f6904.
 40. McQuade DJ, Dargan PI, Wood DM. Challenges in the diagnosis of ethylene glycol poisoning. *Ann Clin Biochem* 2014;51:167-78.
 41. Marwick J, Elledge RO, Burtenshaw A. Ethylene glycol poisoning and the lactate gap. *Anaesthesia* 2012;67:299.
 42. Manini AF, Hoffman RS, McMartin KE, Nelson LS. Relationship between serum glycolate and falsely elevated lactate in severe ethylene glycol poisoning. *J Anal Toxicol* 2009;33:174-6.
 43. Desai RA, Liu-Mares W, Dausey DJ, Rosenheck RA. Suicidal ideation and suicide attempts in a sample of homeless people with mental illness. *J Nerv Ment Dis* 2003;191:365-71.
 44. Prigerson HG, Desai RA, Liu-Mares W, Rosenheck RA. Suicidal ideation and suicide attempts in homeless mentally ill persons: age-specific risks of substance abuse. *Soc Psychiatry Psychiatr Epidemiol* 2003;38:213-9.
 45. Cottler LB, Campbell W, Krishna VA, Cunningham-Williams RM, Abdallah AB. Predictors of high rates of suicidal ideation among drug users. *J Nerv Ment Dis* 2005;193:431-7.
 46. Binswanger IA, Stern MF, Deyo RA, et al. Release from prison — a high risk of death for former inmates. *N Engl J Med* 2007;356:157-65.
 47. Christodoulou C, Douzenis A, Papadopoulos FC, et al. Suicide and seasonality. *Acta Psychiatr Scand* 2012;125:127-46.
 48. Postolache TT, Mortensen PB, Tonelli LH, et al. Seasonal spring peaks of suicide in victims with and without prior history of hospitalization for mood disorders. *J Affect Disord* 2010;121:88-93.
 49. Puopolo PR, Pothier ME, Volpicelli SA, Flood JG. Single procedure for detection, confirmation, and quantification of benzodiazepines in serum by liquid chro-

matography with photodiode-array detection. *Clin Chem* 1991;37:701-6.

50. Petrie MS, Lynch KL, Wu AH, Steinhart AA, Horowitz GL. Prescription compliance or illicit designer drug abuse? *Clin Chem* 2012;58:1631-4.

51. Baron JM, Griggs DA, Nixon AL, Long WH, Flood JG. The trazodone metabolite meta-chlorophenylpiperazine can cause false-positive urine amphetamine immunoassay results. *J Anal Toxicol* 2011;35:364-8.

52. Porter WH. Ethylene glycol poisoning: quintessential clinical toxicology: analytical conundrum. *Clin Chim Acta* 2012;413:365-77.

Copyright © 2015 Massachusetts Medical Society.

LANTERN SLIDES UPDATED: COMPLETE POWERPOINT SLIDE SETS FROM THE CLINICOPATHOLOGICAL CONFERENCES

Any reader of the *Journal* who uses the Case Records of the Massachusetts General Hospital as a teaching exercise or reference material is now eligible to receive a complete set of PowerPoint slides, including digital images, with identifying legends, shown at the live Clinicopathological Conference (CPC) that is the basis of the Case Record. This slide set contains all of the images from the CPC, not only those published in the *Journal*. Radiographic, neurologic, and cardiac studies, gross specimens, and photomicrographs, as well as unpublished text slides, tables, and diagrams, are included. Every year 40 sets are produced, averaging 50-60 slides per set. Each set is supplied on a compact disc and is mailed to coincide with the publication of the Case Record.

The cost of an annual subscription is \$600, or individual sets may be purchased for \$50 each. Application forms for the current subscription year, which began in January, may be obtained from the Lantern Slides Service, Department of Pathology, Massachusetts General Hospital, Boston, MA 02114 (telephone 617-726-2974) or e-mail Pathphotoslides@partners.org.